

Atraumatic Removal of Broken Root Piece- Revival of a Forgotten Technique

Reyazulla M.A.¹, Gopinath A.L.², Abhishek Dutta³

1,2- MDS, Associate professor, Department of Oral And Maxillofacial Surgery, V.S Dental College And Hospital, Bangalore. 3- Post graduate student, Department of Oral And Maxillofacial Surgery, V.S Dental College And Hospital, Bangalore.

Correspondence to:

Dr. Abhishek Dutta, PG Student, Department of Oral And Maxillofacial Surgery, V.S Dental College And Hospital, Bangalore.

Contact Us: www.ijohmr.com

ABSTRACT

Often, when removing a tooth, a surgeon faces a tricky situation when the root fractures. It is an agonizing situation both for the surgeon and the patient. Although, various methods are described in literature for retrieval of a root piece, but they have their own complications. We have done appraisal of a novel method already described in literature but has become obsolete down the lane. It's a relatively atraumatic, less time consuming and does not need any extra armamentarium.

KEYWORDS: Root, Atraumatic Removal, Fracture

INTRODUCTION

The removal of diseased teeth is the cradle where maxillofacial surgeons get trained. Though it appears to be a relatively simple procedure, it is a highly technique sensitive and art of surgeons hand. The ideal tooth extraction is the painless removal of the whole tooth, or tooth root, with minimal trauma to the investing tissues and so that the wound heals uneventfully, and no postoperative prosthetic problem is created.¹ When removing a tooth, the surgeon often hears a familiar cracking sound, which is nothing but the yielding of alveolar bone to apical pressure. However, after removing the tooth, it is seen that the root tip has fractured and is retained in the socket. This is a tricky and potentially dangerous situation.²

Fracture of tooth or root during removal is sometimes inevitable as the tooth may be weakened either by caries or a large restoration. But it mainly occurs due to improper application of forceps to the tooth. It is surprising that root fracture doesn't occur that frequently as it should have happened due to complex curvatures of the root pattern of the extracted teeth. The palatal root fracture of maxillary molars is frequent due to it being slender and at an angulation from the crown.¹ The extraction of fractured root apex of the palatal root requires the inadvertent removal of the large amount of alveolar bone and may lead to the displacement of the fragment into the maxillary antrum or the creation of oro antral communication. Such fragments are better left undisturbed in the vast majority of cases with assurance to the patient. If removal, is attempted it should be preceded by radiographic examination for precise location of fractured root fragment and performed by an experienced operator using the transalveolar method.¹ For every tooth, there is an easy "backdoor" method of extraction. We have revived a simple atraumatic

technique for removal of broken root tip of maxillary teeth which had already been advocated by DLORR and HOWARTH G in 1985, but somehow has become obsolete down the lane due to availability of various other methods.

THE PROCEDURE

Once the root is fractured, calm and reassures the patient. Take the local anesthetic syringe and slowly engage the needle tip in the canal (Fig.1). Once it is engaged, slowly

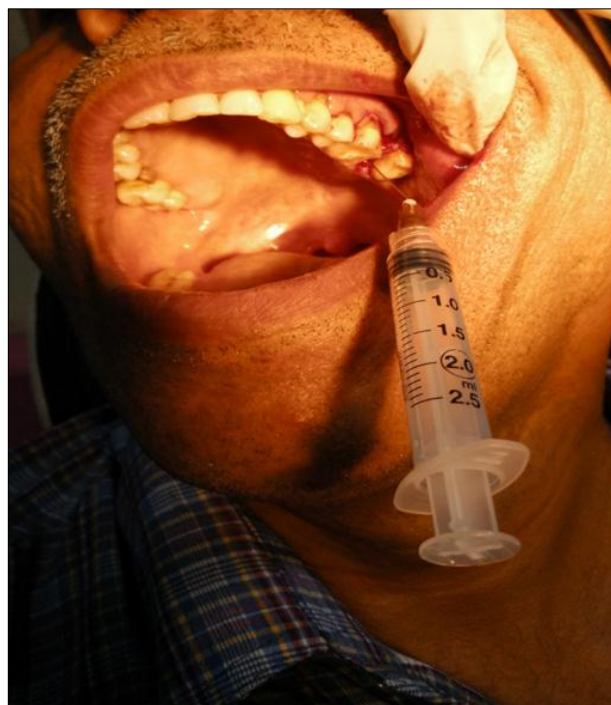


Fig. 1

How to cite this article:

Reyazulla M.A., Gopinath A.L., Abhishek Dutta. Atraumatic Removal of Broken Root Piece- Revival of a Forgotten Technique. *Int J Oral Health Med Res* 2015;2(2):130-132.

taking care pull the needle out, the root fragment comes attached with the needle (fig2). The broken root tip along with the tooth (fig3). It is a very useful and handy technique in situations when there is no access to any other instrument to retrieve the broken root piece. We used this simple novel technique in more than 100 fractured root tip.

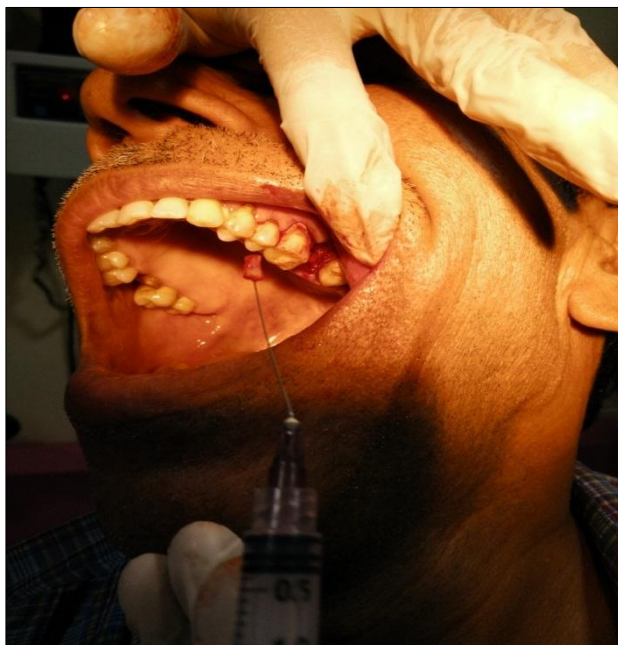


Fig. 2



Fig. 3

DISCUSSION

Peterson, advocated that if a palatal root is broken and has to be removed than a small straight elevator should be used using the wedge principle, to displace the root in occlusal direction, care being taken to apply pressure in gentle wiggling movement.³

Failure to remove the root with an elevator necessitates the removal of the thick interradicular bone using a bur and handpiece under copious saline irrigation, the root is then luxated out by the elevator or forceps. This method is, time consuming and needs an assistant. The use of a dental drill to remove the root has also been described.⁴

Krishnan, used a simple alternative like the barbed broach or a number 40 or 50 endodontic reamer which is wedged tightly into the remaining pulp chamber with one or two clockwise turns, and then removed with a sudden jerk. The palatal root is luxated out attached to the reamers.⁵ H files will engage more effectively in dentin than reamers, and k files. H files do not engage dentin during the insertion motion but engage efficiently to dentin during the withdrawal motion. It will cut the dentin very effectively if the canal is wet, thereby increases chance of instrument fracture.⁶

Plethora of techniques have been propagated in the literature for removal of broken root like creating a bony window above the root apex or removal with apex elevators, periotome, luxators.

This technique has been successfully implemented in our department in more than 100 patients This novel technique has the following advantages:

- It is a relatively easy technique to carry out.
- No invasion of the forceps or elevators, hence complications like displacement of the fragment into the maxillary antrum or the creation of oro-antral communication, is avoided,
- No gross anatomical disturbance,
- No need for specialized instruments,
- No need for closure by suturing,
- No need for an invasive method like transalveolar extraction, hence complications like edema and infection can be avoided.
- No need for assisting surgical personnel and
- Elimination of the apprehension of the patient, associated with the noise and vibration of the surgical hand piece.

It is a technique sensitive procedure however, which one can master with expertise.

CONCLUSION

To conclude we can say that it is a easy, simple and very effective method for retrieving broken root tip of maxillary teeth with minimal collateral damage to the surrounding structures, upholding the essence of atraumatic exodontia .

REFERENCES

1. V. Sadesh Kannan, G. R. Sathya Narayanan, A new atraumatic method of removing fractured palatal root using endodontic Hfiles luted with resin modified glass ionomercement: A pilot study. J Pharm Bioallied Sci. 2014 Jul; 6(Suppl 1): S156–S159.
2. Stoner KE. Using a Hedström endodontic file to retrieve a root tip JADA .2002, Vol. 133, April.

3. Peterson LJ. Principle of complicated exodontia. In: Peterson LJ, Ellis E, Hupp JR, Tucker MR, editors. Contemporary Oral and Maxillofacial Surgery. 4th ed. St. Louis: Mosby; 2003. pp. 179–80.
4. Meyer RE. Removal of roots. In: Waite DE, editor. Textbook of Practical Oral and Maxillofacial Surgery. 3rd ed. Philadelphia: Lea and Febiger; 1987. pp. 151–2.
5. Krishnan B. Removal of fractured palatal root. Br Jr of oral and maxillofacial surgery. 2008;46:421.
6. Zinelis S, Margelos J. Failure mechanism of Hedstroem endodontic files *in vivo*. J Endod. 2002;28:471–3.

Source of Support: Nil
Conflict of Interest: Nil